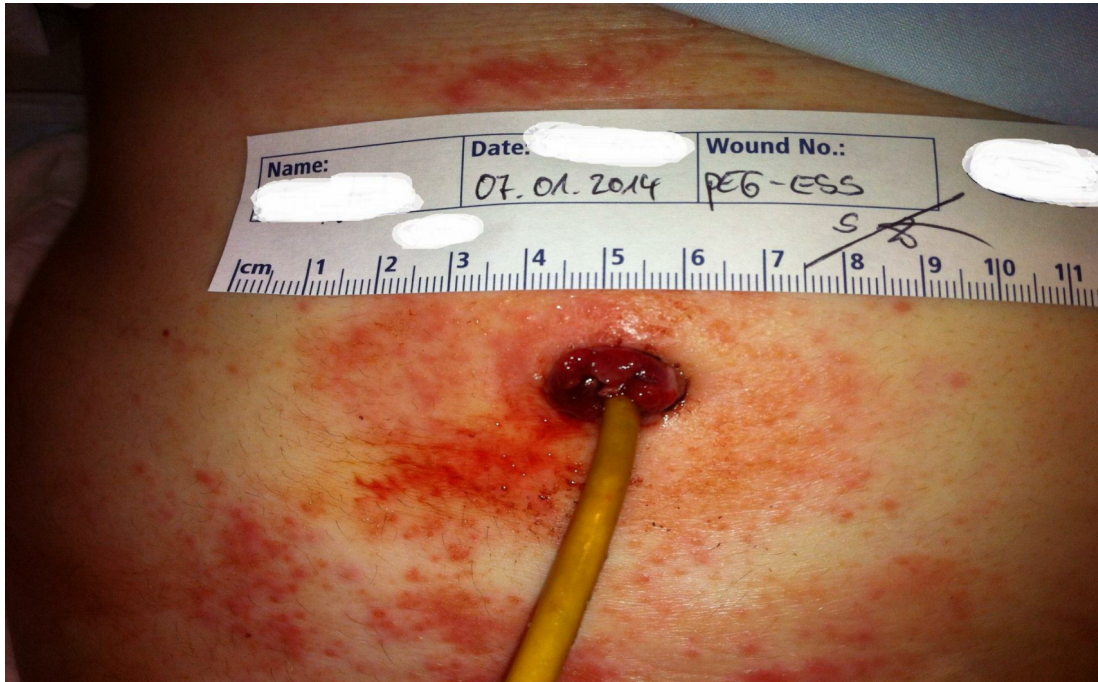

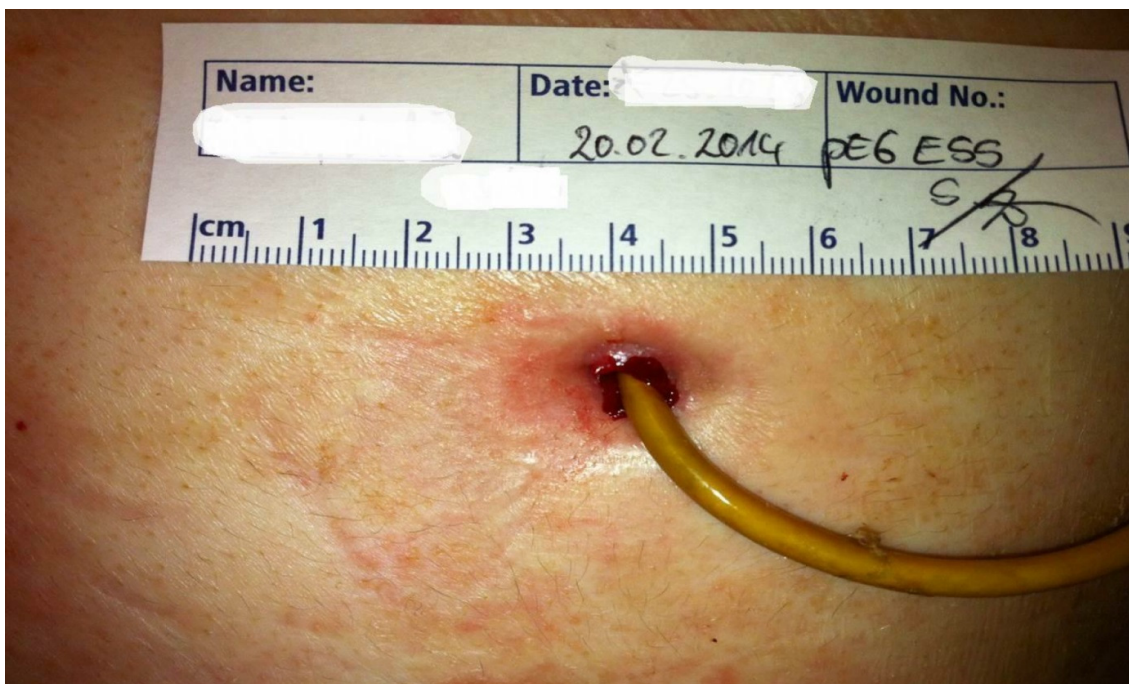CASESTUDY: Application of curea P1drain

(1) – PEG-feeding

46 years old patient (m) with longterm PEG developed a recurrent hypergranulation at the incision. The periwound showed intensive reddening with sanguineous exudate. The hypergranulation grew up to 15 mm above the skin.



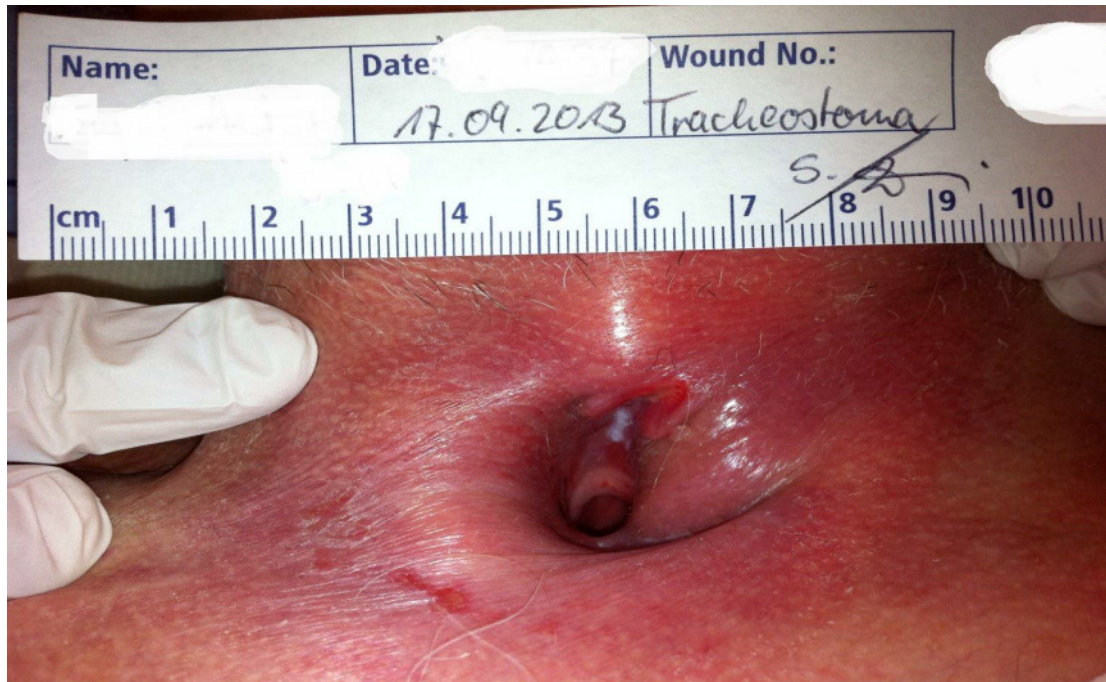To treat with this healing disorder the wound was cleaned with Prontosan regularly and covered with *curea P1drain*. Within short time hypergranulation and irritation were reduced significantly.



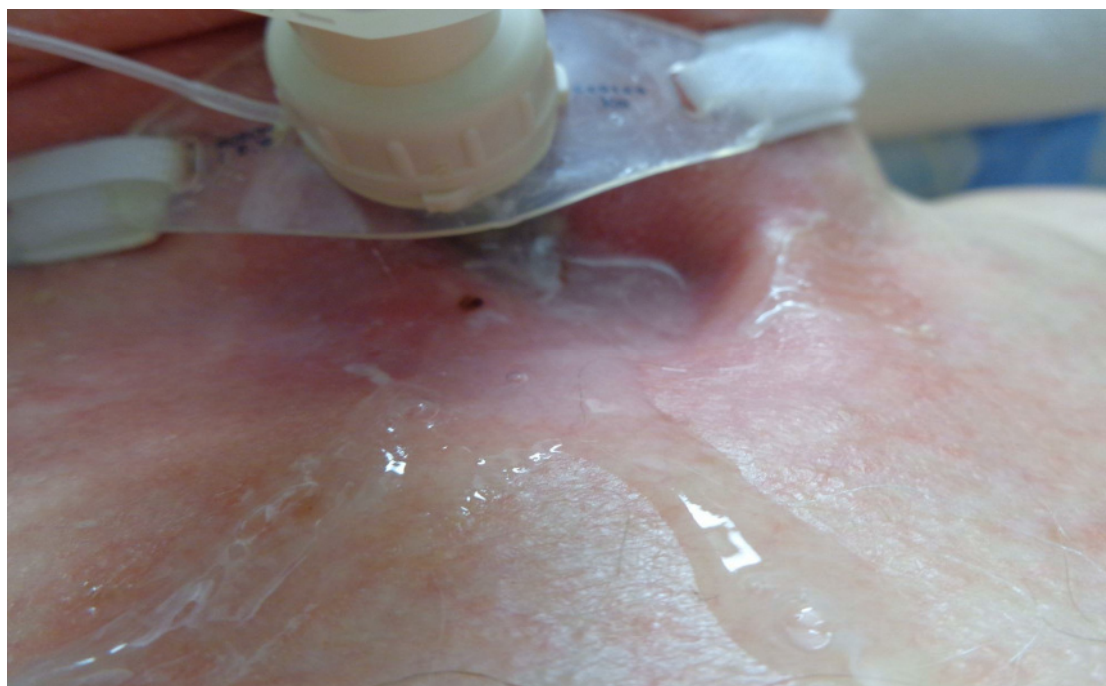
CASESTUDY: Application of curea P1drain

(2) – Tracheostomy

80 year old patient (m) with dilated tracheostomy and intense tracheal secretion. The periwound was reddened, the skin dry (parchment-skin effect) and the tracheostomy showed a lesion in the 12 o'clock position due to mechanical irritation.

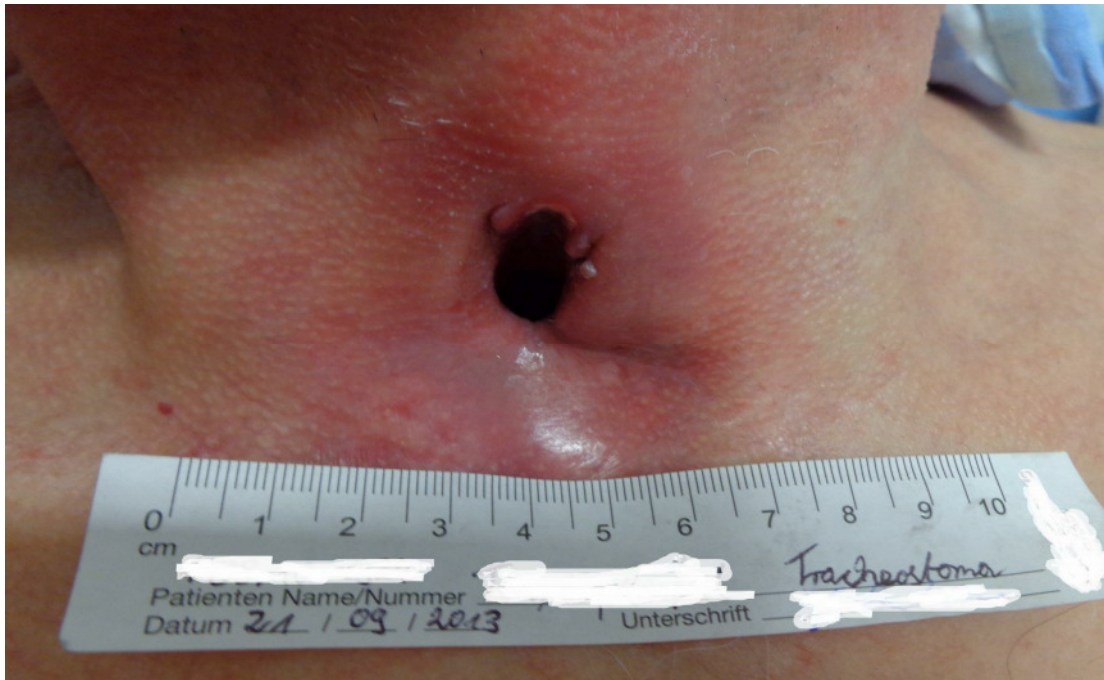

By this time the applied dressing had to be changed every eight hours due to the increased level of secretion.



CASESTUDY: Application of curea P1drain

The picture below shows the wound after five days: Reddening and swelling have been reduced; the dressing had to be changed once a day. This resulted in reduced mechanical irritation leading to less pain and obvious healing tendencies of the lateral lesion.



curea P1drain after 24 hours application: secrete and blood are absorbed, the more visous secretion did not impede the uptake.

